

# Detecting Optic Disc In Digital Fundus Images Using Stochastic Watershed Transformation

J.Jenita Jeba Esther<sup>1</sup>, S.G.Gino Sophia<sup>2</sup>

<sup>1</sup>Mtech Scholar, Department of Computer Science and Engineering, Hindustan University, Chennai, Tamilnadu, India

<sup>2</sup>Assistant Professor, Department of Computer Science and Engineering, Hindustan University, Chennai, Tamilnadu, India

## ABSTRACT

The paper proposed to detecting the optic disc from the fundus image and find the stages of disease early so as to avoid specialist interference. The extraction of optic disc mainly based on the principal component analysis(PCA) and stochastic watershed transformation. The stages of disease can be find by using Extended minimum and maximum transform. The input for the segmentation is obtained by PCA. The purpose of using PCA is to reduce the dimension of the image and to achieve the grey-scale image. Stochastic Watershed transformation is applied in grey-scale images. It is a powerful segmentation tool, in that the minima of the image represent the objects of interest and the maxima represent the separation boundaries between objects. We can implement the algorithm on public databases for results. The main advantage of the detecting of disease early, it does not need specialists care and reduces the consultation time. Finally the optic disc will be detected with the goal of measuring the cup-to-disc-ratio. Thus the system for detecting the patterns of these abnormal cases would supply an excellent benefit.

**Keywords:** *optic disc, fundus, principal component analysis, stochastic watershed transformation, cup-to-disc-ratio.*

## 1. Introduction

Diabetic retinopathy is retinopathy, (damage to the retina) caused by complications of diabetes, which can eventually lead to blindness. [1], [2]. It is an ocular manifestation of diabetes, a systemic disease, which affects up to 80 percent [3], of all patients who have had diabetes for 10 years or more. The longer a person has diabetes, the higher his or her chances of developing diabetic retinopathy. Diabetic retinopathy often has no early warning signs. On the first stage which is called Non-proliferative diabetic retinopathy (NPDR) there are no symptoms, are not visible to the naked eye and have 20/20 vision, but can be detected by fundus photography. On the second stage, as abnormal new blood vessels (neovascularisation) form at the back of the eye as a part of *proliferative diabetic retinopathy*(PDR), they can burst and bleed (vitreous hemorrhage) and blur vision, because the new blood vessels are weak. The first time this happens, it may not be very severe. In most cases, it will leave just a few specks of blood, or spots, floating in a person's visual field, though the spots often go away after a few hours. In colour fundus photograph shown optic disc appears as a bright spot of circular or elliptical shape, interrupted by the outgoing vessels. It can be seen that optic nerves and vessels emerge in to the retina through optic disc. It is located on the nasal side of the macula and it does not contain any photoreceptor. Therefore it

is also called the blind spot. Normally the disease can be detected through regular examination by Ophthalmologist. Because of rise of population, rising levels of obesity and physical inactivity factors, direct examination by the ophthalmologist is the limiting factor. So an automatic detection provides a greater benefit. The optic disc segmentation is the major process for many algorithms. First the optic disc location helps to avoid false exudates. Secondly the OD margin can be used for calculating diameter of the optic disc. Thirdly, the relation between the size of the optic disc and the cup to optic ratio is to find for the diagnosis of glaucoma. There are many Optic disc segmentation methods. Normally the methods can be grouped as template-based models, deformable models and morphological algorithms.

## 2. Related Work

There are numerous OD segmentation methods. The techniques can be grouped into template-based methods, deformable models and morphological algorithms. In template-based methods, edge detection techniques are used and it is followed by Circular Hough Transform, pyramidal decomposition, KNN-regressor. A kNN regressor is utilized to identify the distance in pixels in the image to the object at any given location in the image based on a set of features measured at that location. In the deformable

models, GVF snake, ASM and modified active contours are used to exploit the features of optic disc anatomy. Here Optic Disc is Localised using a Snake. The snake and hand-labelled images to compare the performance of the morphology methods. Most of the algorithms based on mathematical Morphology, it detect the optic disc by using marker-controlled watershed, actually each author choses different marker. The brightest object in the centroid of the image is for the locus of the optic disc and it is used as internal marker. The Extended minima transformation is used to select internal markers and for the partition of image into regions, external marker can be used. Thus the every region contains the single internal marker. Fuzzy convergence is used to determine the origination of the blood vessel network. Fuzzy Convergence and Illumination Equalization is applied here. The Fuzzy algorithm identifies the optic nerve as the focal point of the blood vessel network. Some authors propose various algorithms to get the better detection optic disc boundary

### 3. Proposed Work

The method proposed in this paper is mainly based on stochastic watershed transformation and principal component analysis. The Principal component analysis (PCA) is applied in the preprocessing stage. First the PCA is applied to the RGB fundus image to obtain the grey image, the PCA is mainly used to reduce the dimension of the image then the vessels and the optic disc are identified more clearly to get accurate location of optic disc. Then to make the segmentation easier, vessels are removed. Next, the stochastic watershed transformation is applied, it obtained the watershed region belong to optic disc. The stochastic Watershed Transformation avoid the sub-segmentation problems. Then the centroid is calculated for the optic disc boundary. Then the stages of disease to be find. Finally the cup-to-optic disc ratio is to find the diagnosis of glaucoma.

### 4. Methodology

The detection of optic disc is important for many purposes. the methods related to the OD are focused on locating its center. In the proposed system, first in the preprocessing stage, PCA is applied on the RGB fundus image to obtain the grey image. Then the vessels are removed through image restoring technique to make segmentation easier. Then the stochastic watershed transformation is applied which is a segmentation technique for gray-scale image. then the centroid calculation and circular approximation

have to be done and finally the stages of disease to be find.

#### 4.1. Preprocessing

In preprocessing PCA is applied on the RGB fundus image to obtain a grey-scale image in which all the structures of the retina, vessels and OD are differentiated more clearly, the main aim of this is to obtain a accurate detection of the OD.

#### Principal Component Analysis

The main aim of the PCA is to reduce the dimensionality. Principal component analysis (PCA) is a statistical procedure that uses orthogonal transformation to convert a set of observations of possibly correlated variables into a set of values of linearly uncorrelated variable [20]. The principal component axes will be the eigen vectors of the covariance matrix. so have to find the eigen vector values.

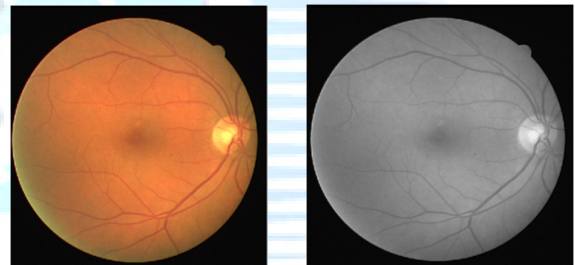


Fig 1. RGB image

Fig 2. Grey scale image

#### Image Enhancement

It enhancing the grey image, the ununiform illumination can be corrected and using the local transformation the contrast is increased.

#### Image Restoring

The image restoring algorithms used in various applications. The aim of this is to restoring the damaged photographs into the removal or replacement of the particular objects [21]. This algorithm is used to fill the selected parts of an image. The main aim is to extract the OD boundary more clearly and reduce the existing borders within the optic disc.

#### 4.2. Optic Disc segmentation

There are various methods for the segmentation. For good efficiency, using stochastic watershed transformation. The centroid of the image also calculated to get the accurate location and finally

region discrimination to be find based on the average intensity of the region.

### Stochastic Watershed Transformation

The stochastic watershed transformation [23] is a segmentation technique for grey-scale image. The algorithm is fully automatic. Moreover this method provides robustness. In this algorithm the minima of the image represents the objects of interest and the maxima of the image represents the

boundaries between objects. This transformation uses the random markers to build the probability density function [10] of contours, then it is segmented for defining the most significant image. The internal marker and external marker to be used.

### Image Centroid calculation

The centroid the image to be calculated using internal and external markers. Mainly the size of the circle is related to the image size, so it is approximated as 15% of the size of the fundus image. Calculating the grey-image centroid combines the centrality of the image with the edge distance. As a result the optic disc is brighter than the background.

### Region discrimination

Based on the average intensity of the region, the discrimination is between the significant and non significant region. The optic disc region will be light region around darker region. Then the threshold is applied on the resulting image to select the valid regions. This operation leads to final OD segmentation.

### 4.3 Post processing

Once the region of interest has been obtained, the results must be obtained to eliminate false contours, which is detected due to blood vessels which crossing through the optic disc. finally the circular approximation has to be done.

### Circular approximation

The optic disc contour has been estimated as a circle [6],[8],[9], although an elliptical shape could also have been chosen. This algorithm is used to establish a zone of the retina concentric to the OD margin. the kasa's method [24] is used to calculate the center and the radius of the circle adapt a binary region through least squares

### 4.4 Stages of disease

The stages of disease can also be find such as mild, moderate and severe. It can be calculated by using the count of microaneurysm in the blood vessel.

The algorithm used here as extended minima and extended maxima transformation and finding the cup-to-disc ratio [5]. The high cup-to-disc ratio will indicate that the fundus is suspicious to glaucoma.

### 5. Advantages of Proposed System

- The automatic detection of optic disc is easily detect the disease.
- It does not require any intervention by specialists and reduces the consultation time.
- Finding the stages of disease make the further treatment easier and reduce the unwanted consultation time
- A system for automatic recognition of the characteristic patterns of these pathological cases would provide a great benefit.

### 6. Architecture

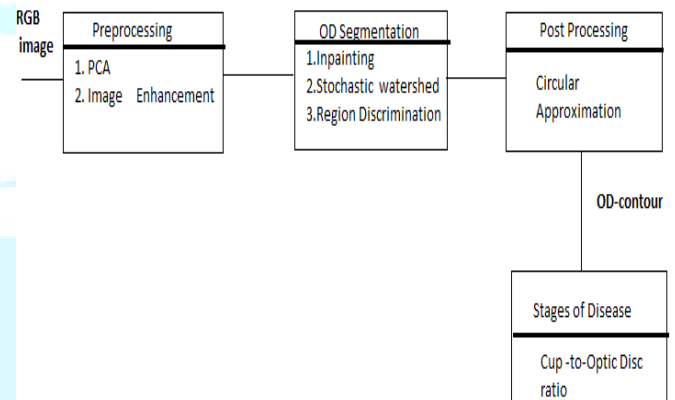


Fig 3 . Architecture

First, the PCA is applied on the RGB fundus image in order to obtain a grey image in which the different structures of the retina, such as vessels and OD, are differentiated more clearly to get a more accurate detection of the OD. This stage is very important since it largely determines the final result. Then, the vessels are removed through inpainting technique to make the segmentation task easier. Next, a variant of the watershed transformation, the stochastic watershed transformation, followed to a stratified watershed, are implemented on a region of the original image.



Finally, it must be discriminated which of the obtained watershed regions belong to the optic disc and which ones are not. A geodesic transformation and a further threshold are used to achieve that purpose. The algorithm is fully automatic, so process is speeded up and user intervention is avoided making it completely transparent. Moreover, the method provides robustness in each processing step. First, it is independent of the database thanks to using PCA.

Secondly, it employs the grey-image centroid as initial seed so that not only the pixel intensity is taken into account. Thirdly, it makes use of the stochastic watershed in order to avoid sub-segmentation problems related to classical watershed transformation. Finally it has to find stages of disease and cup-to -optic disc ratio.

## 7. Conclusion

In this paper, a new approach for the automatic detection of the optic disc and finding the stages of disease has been presented. First, it is focused on the new grey image as input obtained. Secondly, several operations based on mathematical morphology and PCA are implemented with the aim of locating the OD. For that purpose, both stochastic and stratified watershed transformation have been used. The final goal of the proposed method is to make easier the early detection of diseases related to the fundus and find the stages of diseases such as mild, moderate and severe. Its main advantage is finding the disease without interference by clinicians, which releases necessary resources (specialists) and reduces the consultation time, hence its use in primary care is facilitated. The optic cup will also be detected with the goal of measuring the cup-to-disc (C/D) ratio for the diagnosis of glaucoma.

## Acknowledgment

I thank the Lord Almighty who has been with me through every walk in my life, for guiding me and for the blessings showered on me to complete the project in successful manner. I convey my sincere thanks to my guide Ms.S.G.Gino Sophia M.E., Assistant Professor, Department of Computer Science and Engineering, Hindustan University who give her valuable guidance throughout and it is great privilege to express my gratitude to her. I also thank Dr. Jawahar George MD who inspired me and supported me throughout my project.

## References

- [1] D. Pascolini and S. P. Mariotti, "Global estimates of visual impairment:2010," *Br. J. Ophthalmol.*, pp. 614–621, 2011.
- [2] World Health Org., Action plan for the prevention of blindness and visual impairment 2009–2013 2010.
- [3] H. R. Taylor, "Eye care for the community," *Clin. Exp. Ophthalmol.*, vol. 30, no. 3, pp. 151–154, 2002.
- [4] T. Walter, J. C. Klein, P. Massin, and A. Erginay, "A contribution of image processing to the diagnosis of diabetic retinopathy-detection of exudates in color fundus images of the human retina," *IEEE Trans. Med. Imag.*, vol. 21, no. 10, pp. 1236–1243, Oct. 2002.
- [5] J. Liu, D. W. K. Wong, J. H. Lim, H. Li, N. M. Tan, Z. Zhang, T. Y. Wong, and R. Lavanya, "Argali: An automatic cup-to-disc ratio measurement system for glaucoma analysis using level-set image processing," in *13th International Conference on Biomedical Engineering*. Berlin, Germany: Springer, 2009, vol. 23, pp. 559–562.
- [6] M. Niemeijer, M. D. A. Moff, and B. van Ginneken, "Fast detection of the optic disc and fovea in color fundus photographs," *Med. Image Anal.*, vol. 13, no. 6, pp. 859–870, 2009.
- [7] M. Park, J. S. Jin, and S. Luo, "Locating the optic disc in retinal images," in *Proc. IEEE Int. Conf. Comput. Graph., Imag. Visualisat.*, 2006, pp. 141–145.
- [8] A. Aquino, M. E. Gegúndez-Arias, and D. Marín, "Detecting the optic disc boundary in digital fundus images using morphological, edge detection, and feature extraction techniques," *IEEE Trans. Med. Imag.*, vol. 29, no. 11, pp. 1860–1869, Nov. 2010.
- [9] M. Lalonde, M. Beaulieu, and L. Gagnon, "Fast and robust optic disc detection using pyramidal decomposition and Hausdorff-based template matching," *IEEE Trans. Med. Imag.*, vol. 20, no. 11, pp. 1193–1200, Nov. 2001.
- [10] T. Kauppi and H. Kälviäinen, "Simple and robust optic disc localisation using colour decorrelated templates," in *Proc. 10th Int. Conf. Advanced Concepts for Intell. Vision Syst.*, Berlin, Germany: Springer-Verlag, 2008, pp. 719–729.
- [11] A. Osareh, M. Mirmehdi, B. Thomas, and R. Markham, "Comparison of colour spaces for optic disc

localisation in retinal images,” in Proc. 16th Int. Conf. Pattern Recognit., 2002, vol. 1, pp. 743–746.

[12] H. Li and O. Chutatape, “Automated feature extraction in color retinal images by a model based approach,” IEEE Trans. Biomed. Eng., vol. 51, no. 2, pp. 246–254, Feb. 2004.

[13] J. Lowell, A. Hunter, D. Steel, A. Basu, R. Ryder, E. Fletcher, and L. Kennedy, “Optic nerve head segmentation,” IEEE Trans. Med. Imag., vol. 23, no. 2, pp. 256–264, Feb. 2004.

[14] J. Xu, O. Chutatape, E. Sung, C. Zheng, and P. C. T. Kuan, “Optic disk feature extraction via modified deformable model technique for glaucoma analysis,” Pattern Recognit., vol. 40, pp. 2063–2076, Jul. 2007.

[15] C. Eswaran, A. Reza, and S. Hati, “Extraction of the contours of optic disc and exudates based on marker-controlled watershed segmentation,” in Proc. Int. Conf. Comput. Sci. Inf. Technol., 2008, pp. 719–723.

[16] D. Welfer, J. Scharcanski, C. M. Kitamura, M. M. D. Pizzol, L. W. Ludwig, and D. R. Marinho, “Segmentation of the optic disk in color eye fundus images using an adaptive morphological approach,” Comput. Biol. Med., vol. 40, no. 2, pp. 124–137, 2010.

[17] R. C. Gonzalez, R. E. Woods, and S. L. Eddins, Digital Image Processing using MATLAB. New York: Pearson Prentice Hall, 2004.

[18] J. Hajer, H. Kamel, and E. Nouredine, “Localization of the optic disk in retinal image using the watersnake,” in Proc. Int. Conf. Comput. and Commun. Eng., 2008, pp. 947–951.

[19] R. J. Qureshi, L. Kovacs, B. Harangi, B. Nagy, T. Peto, and A. Hajdu, “Combining algorithms for automatic detection of optic disc and macula in fundus images,” Comput. Vis. Image Understand., vol. 116, no. 1, pp. 138–145, 2012.

[20] I. T. Jolliffe, Principal Component Analysis, 2nd ed. New York: Springer, 2002.

[21] M. Bertalmio, G. Sapiro, V. Caselles, and C. Ballester, “Image inpainting,” in Proc. of the 27th Annu. Conf. on Comput. Graph. and Interactive Techniques. New York: ACM Press/Addison-Wesley, 2000, pp. 417–424.

[22] J. Serra, Image Analysis and Mathematical Morphology. London, U.K.: Academic, 1982, vol. I.

[23] J. Angulo and D. Jeulin, “Stochastic watershed segmentation,” in Proc. 8th Int. Symp. Math. Morphol., 2007, pp. 265–279.

[24] C. A. Corral and C. S. Lindquist, “On implementing Kasa’s circle fit procedure,” IEEE Trans. Instrum. Measure., vol. 47, no. 3, pp. 789–795, Jun. 1998.

## Author Profile

1. J. Jenita Jeba Esther, received the bachelor of engineering from Francis xavier engineering college in 2011. She is currently pursuing her M.Tech in department of computer science and engineering in Hindustan University, Chennai. The area research of interest are image processing and Mobile Computing.

2. Ms. S. G. Gino Sophia received her bachelor of engineering in Institute of Road and Transport Technogy, Bharathiyar University in 1997. And also completed her M.E in college in Manonmanium Sundarnar University, Tirunelveli in 2005. Currently is working as an Asst. Professor in Hindustan university, chennai. The area of interest are Image processing and Adhoc Networks. Published 8 papers in International Journal and 3 papers in National Journal. Got Project Fund from TNSCST.